Case Conference 2019
"Which door do I open first?"

Acute & Urgent Care Patient Cases

Larry L. Duenk, M. D.

Associate Clinical Professor of Family Medicine & Anatomy
Medical College of Wisconsin

Medical Director
Marsho Expresscare
(Ascension-CSM)
Sheboygan, WI

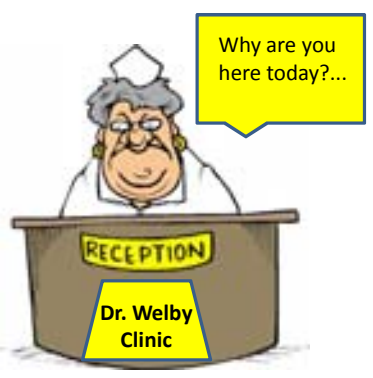

Goals, Comments, Disclaimer:

Goal: Participants will improve clinical skills as I present 10 real urgent care cases and we work through them interactively...applying evidenced based medicine to determine the diagnosis and then treat the patient.

Notes: 1. Don't look ahead as the slides are not in order, and you will "ruin the surprise"..
2. Employed by MCW and Ascension/CSM Healthcare. No other financial disclosures.
3. Always use generic medications when possible(though I occasionally mention brand name medications because of familiarity...)

Your Urgent Care Patients....

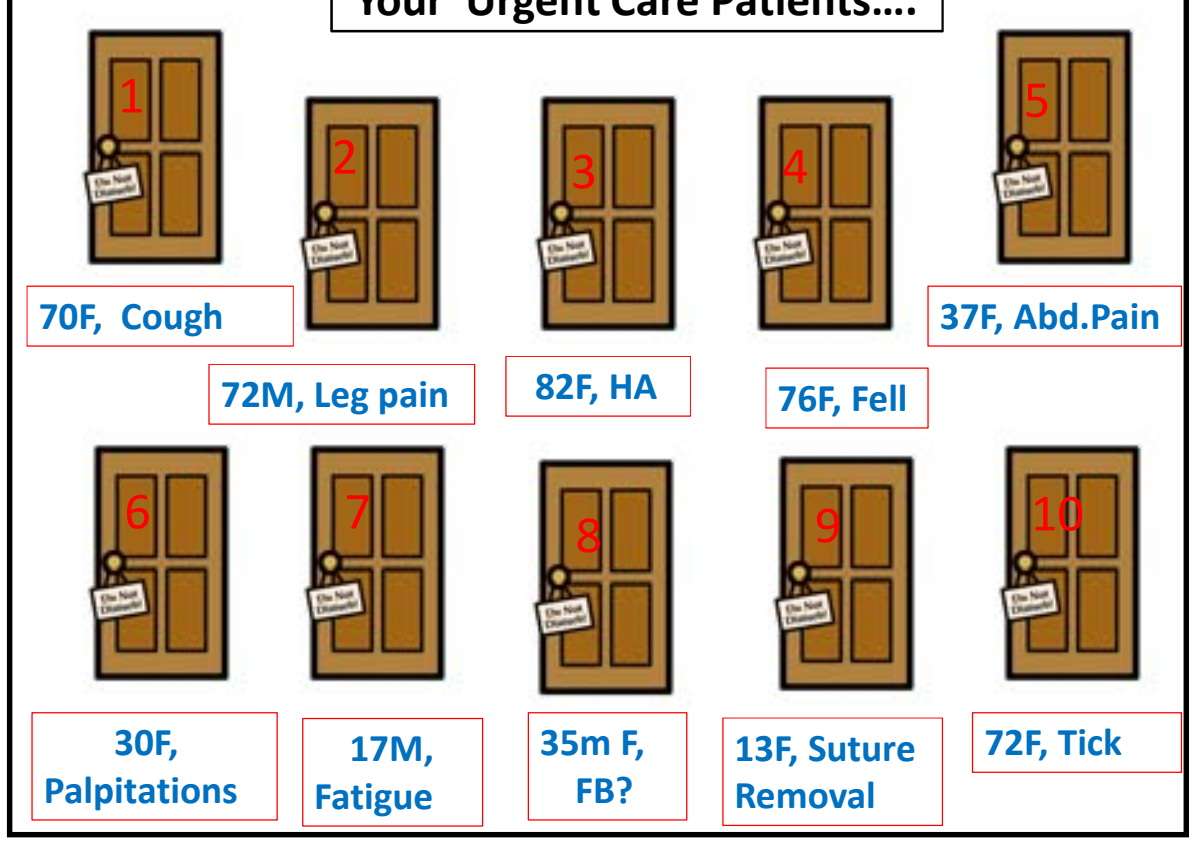

Door 1

- 70 F
- 4d hx. Non-productive cough. Wants codeine cough med
- No dyspnea. No wheezing. No fever.
- PMHx: Asthma. GERD. LBP. Hx. PE(Warfarin continues). Cataracts. Hyperlipidemia. Spinal stenosis(uses walker)
- Allergies: PCN. MS.
- Differential Dx? Labs? Imaging?

Door 1

- Exam: RR 18. Pulse ox 96% RA. BP 136/74. HR 74 Reg. Lungs CTA. No JVD. No leg edema. Left conjunctival hemorrhage.
- Labs: CXR? Other labs?
- DX? Plan?

Door 2

- 62 M, 7-8 weeks leg/thigh weakness, hard to get up when seated.
- No trauma hx. Worse in morning. No bowel or bladder changes. No upper extremity nor other weakness.
- Started a few days before bilateral carpal tunnel surgery
- Past Hx: Aortic valve regurg., bicuspid A. valve. Hx. "bladder tumor". HTN. Diverticulosis. Low Vitamin D.
- Differential Dx? Labs? Other?

- Exam: VSS. Very hard for patient to stand up from chair.
- No other spine nor pelvic girdle nor hip/thigh findings. No muscle wasting. Normal knee/lower legs/ankles/feet. Upper extremities normal. Normal strength, sensation in lower extremities.
- 30 minutes later, No difficulty rising from seated position.
- Normal heart exam. No murmur. Normal peripheral pulses and perfusion.
- Labs?(consider CMP, CK, ESR, CBC, other?) Imaging?(probably not unless other symptoms)
- Diagnosis and take home message…….

Door 2

82 F, with adult son & Hmong translator: "HA x 20 hours."
PMHx: HTN, CAD, CHF, DM, CVA, COPD. "Recent stroke in 38 y/o son(different son)…"
Pt. notes: "similar to prior HA's past few yrs. when BP elevated".
"1/10 now, was 3/10 last night".
No other neuro symptoms.
No dyspnea. No chest pain.
No other symptoms.
Diff. Dx: Labs? Imaging? ED?

Door 3

Exam:

Door 3

Appears fatigued.
HR: 72. BP: 181/110 (Right and left arm similar; 150s/90s at past visits). RR: 16. T: 98.3. Pulse Ox: 95% RA. BMI: 31.9.
HEENT: wnl. Neck: No JVD, No thyromegaly, No bruits. Lungs CTA. Heart: RRR, no murmur. Good peripheral pulses. Neuro: Motor/CN/ Sensation/Cerebellar all normal. No drift. Gait wnl. Speech wnl. Memory, judgement seem wnl(communication via translator).
Labs? Imaging? Treatment?…….
Diagnosis is………

Door 4

- 76 y/o F, stumbled today on steps..
- Caught right hand and wrist on railing to break fall…
- Right snuffbox pain.
- PIP pain, right 5th finger.
- No other complaints.
- Differential dx? Imaging? Labs?



Exam: VSS. Ambulating w/o difficulty.
R Up. Extremity: Right snuffbox tenderness. Unable to extend distal right 5th finger at PIP. Pain at PIP

HEENT, neck, chest, abdomen, back, pelvic girdle, other extremities: all negative for trauma.

X-rays: Right wrist and scaphoid: negative.
Right hand: negative.

Ultimate dx. ? Plan?
Take home message……

Door 4

Door 5

- 37 y/o "LLQ abd. pain x 2-3 days."
- "Worse standing, absent seated.."
- PO does not aggravate nor alleviate.
- Normal BM, no melena/blood.
- No N/V. "No bulges/hernia."
- No urinary/renal colic Sx., No repro. Sx.
- No fever. No other ROS changes.
- PHx: "FmHx. PT gene mutation: On warfarin long term: PE Hx., Kidney stone age 16."
- FmHx: "Brother with abd. circulation clot"(DVT?), pt. concerned about this possibility……
- Differential Dx? Labs? Imaging? Other?

Door 5

Exam: VSS(HR: 80, BP: 102/62, RR: 18, T: 98.7). Abdomen: Mild-mod. tenderness LLQ(otherwise NTR). Normal BS. No distension. No organomegaly. (No prior abd. Surgery)
HEENT/Neck: WNL. Lungs CTA. Heart: RRR, good perfusion… Back; NTR, No CVA. Repro: declined.
Skin: WNL, no pallor or change.

Differential DX.?
Labs? Imaging? Pain meds/IVF? Other?
Ultimate Dx. Was:

Door 6

- 30 y/o F, long hx. Palpitations many years, less so past 1 year. Hx. MVP.
- Increased past 2 weeks: "A few times/day lasting minutes to hours. Last night several hours".
- Slight fatigue with symptoms. No CP nor dyspnea with symptoms.
- Has cardiologist, but "has not seen for 1-2 yrs."
- Hx. chronic LBP: "Vicodin 5/300 qid prn, or Tramadol 50mg, 1 po qid prn."

- Differential Dx.:
- Imaging? Labs? Other?

Exam: (No symptoms now): HR: 76, RRR. BP: 117/78. RR:16. T: 98.1 BMI: 23.9
Appears well.
HEENT: wnl. Neck: wnl. Lungs: CTA. Cor: RRR(at time of exam), no murmurs, no gallops.
Abd: wnl. Extremities: wnl, normal pulses.

Labs: CBC, BMP, TSH wnl. Telemetry: NSR with rare PAC ("1-2 second palpitation symptom" with PAC). 48hr. Holter pending.
Plan: ?.....
Take home message…….

Door 6

Door 7

- 17 y/o M. Here with father.
- 1 week fatigue, HA, poor sleep, urinary symptoms.
- No fevers. No known mono or strep throat exposures. BB player. No sig. past/family hx.
- No travel hx. No drugs, ETOH.

- Differential Dx.?
- Labs? Imaging?

Exam: BP: 126/60. HR 76. RR 16. BMI 17.5. Pt. appears fatigued.
HEENT/Neck: dry lips. No oral erythema/exudate. Lungs: CTA. Cor: RRR. Abdomen: normal exam, no suprapubic/CVA pain. Genitalia: no symptoms, exam deferred. Skin: dry, no pallor. No lymphadenopathy.

Labs: ? Blood tests?, Urine test?, Imaging?

Course: Pt. wanted to go home while waiting for CBC, CMP, Mono, TSH, urine tests.

Differential Dx. ?
Final Diagnosis and treatment…………

Take Home Message………..

Door 7

Door 8

- 35 month old "swallowed cat toy"
- "8 hours ago while dad was watching child – he forgot to mention it…."
- Dad saw pt. playing with toy, then "choking sounds a few seconds". Cat toy then missing…
- Eating and drinking well since. No BM yet
- No sample brought. "fuzzy compressible metallic kitty ball". (per mom who brought pt. to U.C.)

- Differential Dx:?

PE: VSS. Appears well. Talking well.
HEENT/Neck/Lungs:
Normal oral exam. Neck normal, no stridor, etc. Lungs CTA
GI: Soft. NTR. Normal BS.

Differential Dx.?
Imaging?

Sparkle Ball Cat Toys

Door 8

Abdominal and Chest X-ray:

Dx: No FB seen on x-ray.
Plan: Supportive care. Check all stools until FB found. ER/Recheck if symptoms
Take Home Message….

Door 8

Door 9

- 13 y/o female: suture removal right foot.
- Stepped on glass at home 10 days ago, laceration right plantar foot at arch.
- ED day of injury: 7-8 sutures.
- Accompanied by mother.

- Questions?
- Let nursing staff remove sutures?

Door 9

PE: Appears well. Ambulatory w/o difficulty
Right foot wound appears to be healing well.

Mom: "What about the numbness and toe curling?......"

Pt. describes "numbness" distal to wound and 1 cm proximal; "and can't curl my toes anymore since day of injury".
Further exam confirms decreased sensation distal and 1 cm proximal to healing wound. Pt. not able to flex toes 1-4/5 well(compared with uninjured left foot)

Differential Dx. Now: ? Imaging? Referral? Remove sutures?

Door 10

- 72 y/o: F, likely deer tick bite past 1-2 days northern WI while at "the cottage".
- Pt. "removed bulk of tick at home but small black part remains left elbow"…
- No other symptoms or problems.
- Tetanus immunization up to date.
- "Wants tick part removed".
- Differential Dx.? Labs? Imaging?

Door 10

PE: Appears well.
VSS.

Skin: small black FB (consistent with tick part) embedded in skin above left antecubital area. Approx. 1mm x 5mm long.

DX: ? Plan: ?

Case 1, Take Home Message:

- No CXR. INR=5.4
- Diagnosis: Viral URI and bronchitis with cough. Left conjunctival hemorrhage.
  Elevated INR.

Treatment plan: Supportive care. Codeine cough medicine(PDMP OK). Adjust warfarin dose.
Recheck 3 days.

Take home message: Always review past hx/problem lists and medications and consider additional diagnoses related to comorbidities

Case 2, Take Home Message:

- ESR 95 mm/hr: Polymyalgia Rheumatica
- CMP normal. CK normal (55unit/L)
- Prednisone 40mg po daily x 10 days. See PMD within 10 days.(discussed with PMD on dos.)
- Think of PMR in older pts. with proximal thigh pain which is worst in the morning and improves during the day as pt. is "up and around".

Case 3, Take Home Message:

- Diagnosis: Hypertensive Urgency
- Pt. to ED: Head CT, EKG, both w/o acute finding. No labs. "Headache now gone". BP: 169/94 at ED discharge without ED meds. Discharged with education to take HTN and other meds. And follow up with own doctor soon….
- "Pt. likely had increased BP because of recent change from Metoprolol to Amlodipine 5 mg daily"
- Is patient's acute BP elevated from her/his recent baseline? Is pt. compliant with meds? Other issues/substances causing elevated BP?: caffeine, cocaine, "white coat"…etc.
- Are there end organ symptoms? (1. Hypertensive Urgency/Emergency: consider ED. 2. Is there a place for clonidine: 0.1 mg po acutely?(Rebound risk, must go home on clonidine and wean slowly…)

Case 4, Take Home Message

Diagnosis:

1. Extensor injury R 5th finger.("Mallet finger")
   Treatment: "Stax splint"
2. Right wrist sprain.
   Treatment: wrist splint. RTC if scaphoid pain persists.

- Pt. must not remove "stax splint" if extensor injury is to heal.
- RTC and repeat x-ray/etc./ if scaphoid pain persists.

Case 5, Take Home Message

- CBC, CMP, Lipase/Amylase, Abdominal x-ray series all wnl. Preg. Negative.
- INR 1.6
- UA: + Esterase. Micro: 21-30 WBC, 11-20 RBC, Mod. Bact., Epi: 11-20.
- Summary: likely cystitis: Bactrim. No change in warfarin as Bactrim will increase INR….
- May be other undiagnosed problems: pt. declined abd.-pelvic CT for now….

Take home message: "Common problems occur commonly…"

Case 6, Take Home Message:

- Palpitations are relatively common in young women, especially with hx. of MVP.
- Consider labs: TSH, BMP, CBC, UDS? And Holter/Event monitor. Other?
- Eliminate caffeine, decongestants, etc.
- Consider echocardiogram/cardiology consult

Case 7, Take Home Message:

- Glucose: 1092. Na: 131. Cl: 87. HgbA1c: 12.6. K: 5.3. Hgb: 16.3. Hct: 49.5%. TSH wnl.
- Diagnosis: Hyperglycemia: New onset DM1
- Plan: To ED for hydration, insulin, K+; admit.

Take home message: Fatigue with polyuria, polydipsia may be new onset DM1.

Case 8, Take Home Messages:

- Is the History consistent with the exam? Was there really an ingestion?
- Prevention is easier than extraction/endoscopy.
- Have parent/caregiver bring sample of potentially swallowed object: lay sample on x-ray table next to pt. when shooting x-rays for possible FB: If sample is seen on x-ray, any swallowed or other FB should also show on x-ray……
- Some objects must be removed if swallowed: button batteries, etc. Call CHW/poison control for advice.

Case 9, Take Home Message:

- Pt. likely has nerve and/or tendon injuries
- Referred to ortho
- Did not remove sutures

*

Take home messages: 1. “Suture removal” visits should be called “Wound checks” and appropriate exam done before suture removal. 2.* Don’t rush to take out sutures too soon: wound dehiscence often occurs.

Case 10, Take Home Message:

- Diagnosis: Deer tick bite, Deer tick FB arm
- Treatment: Doxycycline 200 mg po once for Lyme Disease prophylaxis
- My procedure: Discuss with pt.: Betadine, 2% Lido injection. Superficial incision “over” tick FB, “tease out” FB with scalpel blade and small splinter forceps.(Audience suggestions?)

Take Home Message: 1. Doxy. 200 mg po once for Lyme prevention if recent engorged deer tick in skin from Lyme endemic area(Sanford Abx. Guide). 2. Various approaches to FB removal: Use good judgement…

The End
Larry Duenk, MD
January 2019